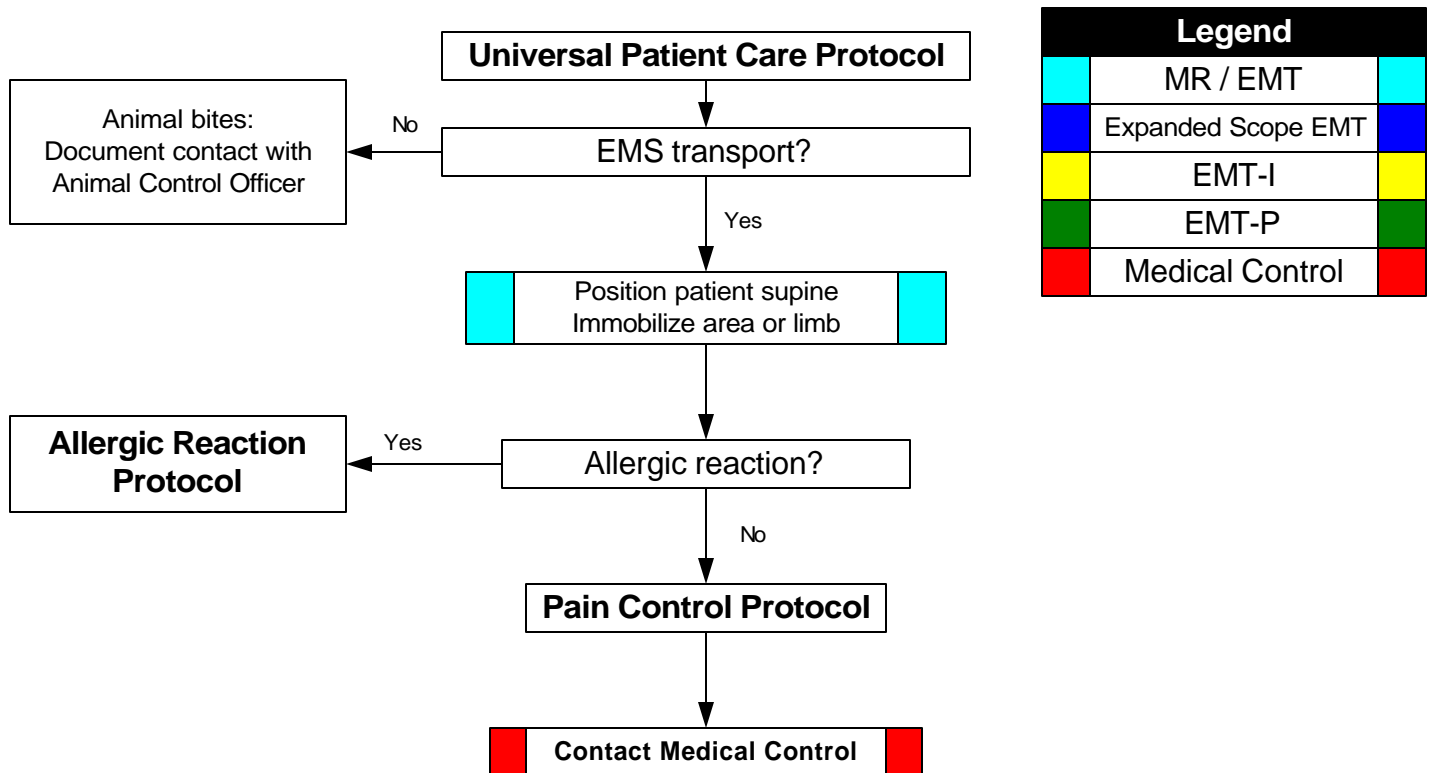


FORSYTH COUNTY EMS Trauma Protocols

Bites and Envenomations

History: <ul style="list-style-type: none"> * Type of bite / sting * Description or bring creature / photo with patient for identification * Time, location, size of bite / sting * Previous reaction to bite / sting * Domestic vs. Wild * Tetanus and Rabies risk * Immunocompromised patient 	Signs and Symptoms: <ul style="list-style-type: none"> * Rash, skin break, wound * Pain, soft tissue swelling, redness * Blood oozing from the bite wound * Evidence of infection * Shortness of breath, wheezing * Allergic reaction, hives, itching * Hypotension or shock 	Differential: <ul style="list-style-type: none"> * Animal bite * Human bite * Snake bite (poisonous) * Spider bite (poisonous) * Insect sting / bite (bee, wasp, ant, tick) * Infection risk * Rabies risk * Tetanus risk
---	--	--



Pearls:

- * **Exam: Mental Status, Skin, Extremities (Location of injury), and a complete Neck, Lung, Heart, Abdomen, Back, and Neuro exam if systemic effects are noted.**
- * Human bites are much worse than animal bites due to normal mouth bacteria.
- * Carnivore bites are much more likely to become infected and have risk of Rabies exposure.
- * Cat bites may progress to infection rapidly due to a specific bacteria (*Pasteurella multocoda*).
- * Poisonous snakes in this area are generally of the pit viper family: rattlesnake, copperhead, and water moccasin.
 - * Attempt to identify snake if possible.
 - * Coral snake bites are rare: Very little pain but very toxic.
 - * Amount of envenomation is variable, generally worse with larger snakes and early in spring.
 - * If no pain or swelling, envenomation is unlikely. (after 2 hours)
- * Black Widow spider bites tend to minimally painful, but over a few hours, muscular pain and severe abdominal pain may develop (spider is black with red hourglass on belly).
- * Brown Recluse spider bites are minimally painful to painless. Little reaction is noted initially but tissue necrosis at the site of the bite develops over the next few days (brown spider with fiddle shape on back).
- * Evidence of infection: swelling, redness, drainage, fever, red streaks proximal to wound.
- * Immunocompromised patients are at an increased risk for infection: diabetes, chemotherapy, etc.

Approved by: _____

R.L. Alson, M.D.
November, 2003