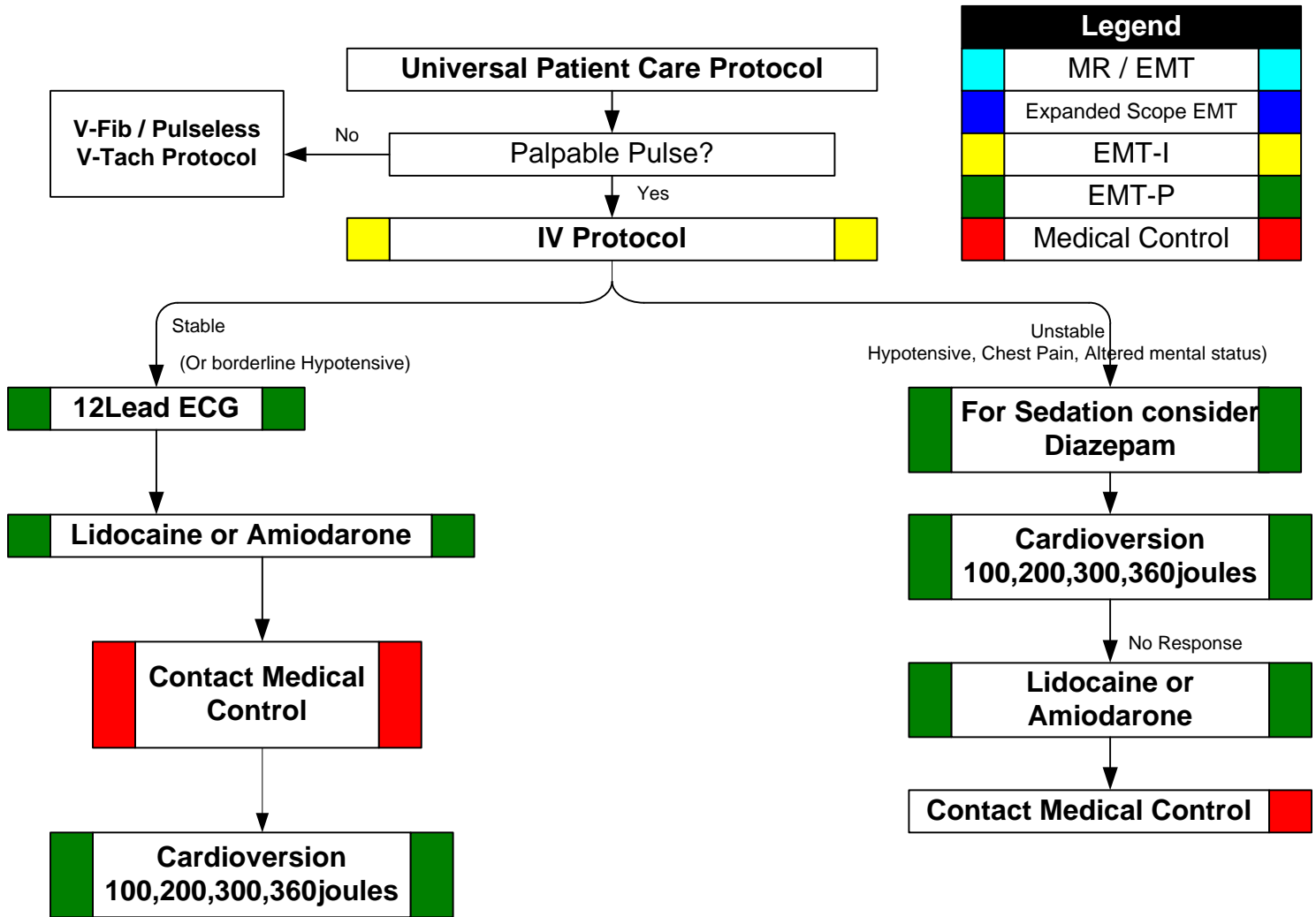


# FORSYTH COUNTY EMS MEDICAL PROTOCOLS

## Ventricular Tachycardia

<b>History:</b> <ul style="list-style-type: none"> <li>* Past medical history / medications, diet drugs.</li> <li>* Palpitations</li> <li>* Syncope / near syncope</li> <li>* Pacemaker</li> <li>* Allergies: lidocaine / novacaine</li> </ul>	<b>Signs and Symptoms:</b> <ul style="list-style-type: none"> <li>* Ventricular tachycardia on ECG (Runs or sustained)</li> <li>* Conscious, rapid pulse</li> <li>* Chest pain, shortness of breath</li> <li>* Dizziness</li> <li>* Palpitations</li> <li>* Rate usually 150-180 bpm for sustained V-Tach</li> </ul>	<b>Differential:</b> <ul style="list-style-type: none"> <li>* <b>Artifact / Device failure</b></li> <li>* <b>Cardiac</b></li> <li>* <b>Endocrine / Metabolic</b></li> <li>* <b>Drugs</b></li> <li>* <b>Pulmonary</b></li> </ul>
--	--	---



**Pearls:**

- \* **Exam: Mental Status, Skin, Neck, Lungs, Heart, Abdomen, Back, Extremities, Neuro**
- \* **Consider brief trial of antiarrhythmic for unstable patient.**
- \* For witnessed / monitored ventricular tachycardia, try having patient cough or deliver a precordial thump.
- \* **Polymorphic V-Tach (Torsades de Pointes) may benefit from the administration of magnesium sulfate.**